

Aggressive Central Giant Cell Granuloma in a Child: A Case Report and Review

Voleti Sri Srujana Aravinda, K. Bala Krishna, K. Chaitanya Ram, M Ravi Shekhar, I Naga Malleswarao.

ABSTRACT

Introduction: An aggressive variant of central giant cell granuloma in a paediatric patient is a localized benign osteolytic proliferation. The lesion consist of fibrous tissue with haemorrhage, hemosiderin deposits and presence of osteoclast-like giant cells with reactive bone formation. Clinically shown with rapid growth, resorption of roots, displacement of teeth and thinning or perforation of cortical bone, and marked recurrence.

Case presentation: A 9-year-old boy reported with a 3 days history of asymptomatic soft tissue swelling in left mandibular posterior region which was diagnosed as central giant cell granuloma based on clinical, radiological and histopathological features.

Management and Prognosis: Surgical resection was performed without any signs of recurrence on 9 months follow up.

Conclusion: Prompt diagnosis and treatment of Central giant cell granuloma can significantly improve morbidity and long-term outcomes.

Key words: Aggressive giant cell granuloma, Central giant cell granuloma.

Oral and Maxillofacial Pathology Journal (2022): <https://www.ompj.org/archives>

INTRODUCTION

WHO defined central giant cell granuloma (CGCG) as a localized benign but sometimes aggressive, osteolytic proliferation consisting of fibrous tissue with hemorrhage and hemosiderin deposits and presence of osteoclast-like giant cells with reactive bone formation.¹ It accounts for less than seven percent of all the benign tumors of jaws, with a 2:1 predilection to the mandible. The lesion tends to cross the midline, with the most frequent site of occurrence being the body of the mandible anterior to the first molars². The peak age of incidence is between 10-25 years³ with a slight female predilection⁴. The etiology is unknown but seems to be related to trauma, inflammatory foci or may be genetically predisposed.^{3,6} It is further divided into two variants aggressive and non-aggressive⁷. Both variants show a localized solitary lesion that has an insidious clinical course identified incidentally⁶.

The non-aggressive variant presents as a painless, slow-growing lesion with an expansion of the cortical bone. The aggressive counterpart is generally greater than 5 cm in size with rapid growth, resorption of roots, displacement of teeth and thinning or perforation of cortical bone, and marked recurrence.⁷⁻⁹ The Radiographic features include well defined unilocular or multilocular radiolucency, saucerisation, or cup-shaped resorption of subjacent alveolar bone.¹⁰ The present report is an aggressive variant of central giant cell granuloma in a pediatric patient with a brief insight into its diagnostic approaches and treatment challenge.

CASE REPORT

A 9-year-old male patient came to the Department of pedodontics with a chief complaint of rapidly enlarging painless swelling on the left side of the face in the lower jaw region. The history of the present illness revealed that the swelling was first noticed one month ago, which was small initially but rapidly increased to

¹ Department of Paediatric and Preventive Dentistry, Anil Neerukonda Institute of Dental Sciences, Visakhapatnam, Andhra Pradesh, India; Department of Oral and Maxillofacial Surgery, Anil Neerukonda Institute of Dental Sciences, Visakhapatnam, Andhra Pradesh, India.

Corresponding author: Voleti Sri Srujana Aravinda, Anil Neerukonda Institute of Dental Sciences, Visakhapatnam, Andhra Pradesh, India. Email: srujanaaravinda1@gmail.com

How to cite this article: Srujana Aravinda VS, Krishna KB, Ram KC, Shekhar MR, Malleswarao IN. Aggressive Central Giant Cell Granuloma in a Child: A Case Report and Review. Oral Maxillofac Pathol J 2022; 13(1): page no. 51-54

Source of Support: Nil

Conflict of Interest: None

Acknowledgments: 1. Dr. Rama Krishna S MDS, Oral and Maxillofacial Surgery; 2. Department of Anaesthesiology, Anil Neerukonda Medical Hospital – For Providing The Operation Theatre.

its current size in 3 days. The medical history was inconsequential; neither a history of trauma was reported.

On extraoral examination, the face was asymmetrical on the left side, swelling extending from the mid of the lower lip to the submandibular region. (Fig 1) The overlying skin was normal in color with no visible secondary changes. The TMJ (Temporomandibular Joint) and condylar movements were bilaterally synchronous with unrestricted mouth opening. There was no regional lymphadenopathy.

On intraoral examination, a roughly oval, fiery red, bulbous, sessile lobulated gingival overgrowth was noted on the left side

of the mandible on the buccal aspect of the gingiva over the alveolar ridge measuring approximately 2 x 1.5 cm extending from distal aspect of 31 to mesial aspect of 75 involving 31,32,73,74,75 with obliteration of the buccal vestibule. The lesion was extended to the lingual aspect of the gingiva in relation to 73 with mobility and displacement of a tooth, resulting in occlusion interference. On palpation swelling, all inspector findings are confirmed. Swelling is non-fluctuant, non-tender, soft in consistency, non-compressible, and non-pulsatile. No paresthesia was noted (Fig. 2). Extraction of 73 and incisional biopsy was carried out under Local anesthesia. A representative sample of soft tissue was taken from the center of the lesion and sent for histopathological examination. The tissue was soft, friable, and bled readily.

Orthopantomograph revealed a large radiolucency in the right angle of mandible extending anteriorly from the root tip of 31 and posteriorly up to root tip of 75 and developing canine and first premolar tooth bud. (Fig. 3A) Computed tomography revealed large radiolucency with scalloped margins. the lesion was diverging and expanding with cortical thinning as well as sclerotic margins at places. (Fig 3B) There was pronounced expansion along the inferior border of the mandible in the Para symphysis region, causing its eccentric ballooning involving the entire buccal cortical plate and a significant proportion of lingual cortical plate in the involved area. (Fig 3C) The biochemical and hematological investigations of the patient were all within normal limits. Based on clinical and radiographic presentation, a provisional diagnosis of central giant cell granuloma was made. Differential diagnosis includes pyogenic granuloma, peripheral giant cell granuloma, hemangioma, peripheral ossifying fibroma.

Microscopic evaluation revealed a non-encapsulated mass of fibrous tissue covered by hyperplastic stratified squamous epithelium. Underlying connective tissue showed numerous proliferating multinucleated giant cells within the background of plump ovoid and spindle-shaped mesenchymal cells, bony trabeculae, and many intervening congested blood vessels with foci of hemorrhage and inflammatory infiltrate with no evidence of cellular tumor. The findings observed were suggestive of Central giant cell granuloma. (Fig 4)

TREATMENT:

After diagnosis, the oral and maxillofacial surgery department was consulted. After routine workup, the child was treated under general anesthesia for en block resection of the lesion. In the informed consent of the patient, we explained all the therapeutic possibilities and their possible consequences.

The incision line was marked by the tissue's lesion and healthy margins and local infiltration was given with 1:80,000 adrenaline and 2% lignocaine. A semicircular incision was given, and careful dissection was carried until the lesion's margins were visualized. The mental nerve was identified and retracted posteriorly. Inferior border of the mandible was palpated. The lesion appeared chocolate brown in color interspersed with hemorrhagic areas welling up with blood. The mass had a soft spongy texture. After marking the extent of the lesion, en block resection of the lesion was done along with teeth 31, 32, and 74 extending borders to involve a margin of healthy soft tissue. Specimen were preserved for biopsy. After achieving hemostasis, the overlying sharp bony margins on the cortical plates were smoothed carefully, taking care to avoid any undue pressure to prevent accidental fracture of the already weakened mandible. Next, tunneling of the tissue was done to eliminate entrapment of the lower lip into tissue while healing. This was followed by closure using resorbable vicryl sutures. An extraoral pressure dressing was given to prevent the formation of a hematoma.

Post-operative recovery was smooth and uneventful. Mild postoperative edema and pain were controlled with analgesic and anti-inflammatory drugs. Post operatively there was no neurological deficit related to the mental nerve. The operated site healing was also satisfactory. Histopathological examination of samples of the tissue from the excised specimen confirmed central giant cell granuloma diagnosis. (10x and 40 x magnification). The patient and parents were well educated about the chances of recurrence, owing to which he was put on subsequent follow-up. Nine months follow up visits revealed no signs of recurrence.

DISCUSSION

A wide variety of oral soft tissue anomalies are detected in children. Still, the low frequency at which many of these entities

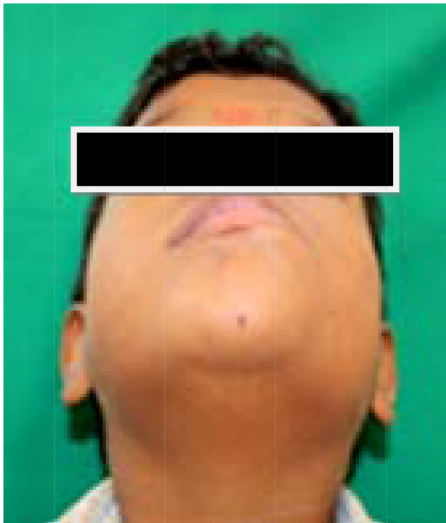

Fig 1: Extraoral Findings - Swelling extending from the mid of the lower lip to the submandibular region.

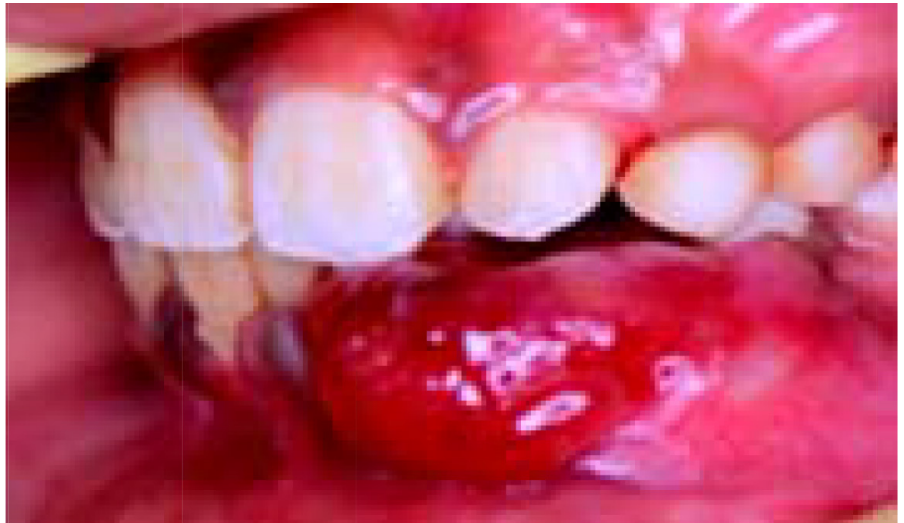

Fig 2: Intraoral Findings- A fiery red sessile lobulated gingival overgrowth.

occur makes them challenging to diagnose clinically. Central giant cell granuloma is an infrequent lesion in daily practice. Therefore, the importance of early detection and knowledge of diagnostic elements of this type of benign lesions, which are destructive with disabling consequences, should be emphasized.

Central giant cell granuloma is not a true neoplasm but a benign hyperplastic reactive lesion related to local irritation or trauma. It was introduced by Jaffe in 1953 as a giant cell reparative granuloma⁴. The reparative term is rejected as the lesions are typically destructive and never reparative. It occurs mainly in children, young adults.¹¹ The etiopathogenesis of CGCG still remains questionable^{12,13}. It has been suggested that CGCG is the result of an exacerbated reparative process related to intraosseous hemorrhage or previous trauma that triggers the reactive granulomatous process, inflammatory foci, and genetic predisposition¹⁴⁻¹⁷.

A study by Chuong in 1986 proposed that CGCG can be divided into two forms based on clinical and radiographic features: The non-aggressive variant presents as a painless, slow-growing lesion with an expansion of the cortical bone, whereas aggressive lesions are generally greater than 5 cm in size, rapid growth, resorption of roots, displacement of teeth, thinning or perforation of cortical bone, and marked recurrence.^{7,9}

Radiographic features of CGCG include well-defined unilocular or multilocular radiolucency, saucerisation, or cup-shaped resorp-

tion of subjacent alveolar bone¹⁰. Most of the features of aggressive form fit well with our case, which led us to our consideration as such.

The radiographic appearances of CGCG vary greatly and may be confused with that of many other lesions of jaws¹⁴. Radiological findings of CGCG are diverse, ranging from small unilocular lesions to large multilocular lesions with a displacement of tooth germs and teeth, root resorption, and cortical perforation⁷. Conventional two-dimensional radiography is generally the first imaging modality performed. However, it provides limited information regarding the cortical integrity, size, and extension of the lesion; thus, imaging providing more in-depth detail such as three-dimensional imaging is preferred¹⁸⁻¹⁹. In addition, cortical disruptions and soft tissue involvement can be better appreciated by three-dimensional imaging such as CT help us to define the extent of the lesion and its internal structure for diagnostic baseline.

The diagnosis of GCG is clinical, radiological, and above all biological and anatomopathological in nature²⁰.

According to WHO definition in 2005, the diagnosis of CGCG has to be confirmed by biopsy. On histological examination, these lesions include a fibrovascular stroma of reactionary form. We find a variable proportion of areas of dense fibrous tissue, multinucleated giant cells, hemosiderin deposits, and occasionally spans of osteoid or bone tissue²¹. Incisional biopsy helped us to narrow down the

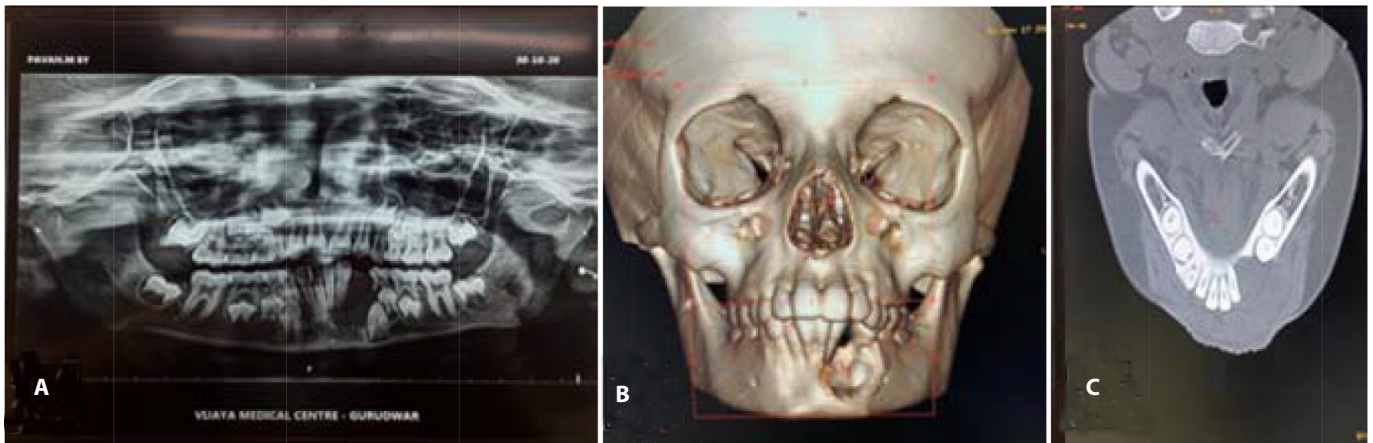


Fig 3: **A.** Orthopantomograph: A large radiolucency in the right angle of mandible. **B.** 3D Computed tomography: Large radiolucent lesion with scalloped margins, diverging and expanding with cortical thinning as well as sclerotic margins at places. **C.** 2D Computed Tomography: Pronounced expansion along the inferior border of the mandible in the Para symphysis region.

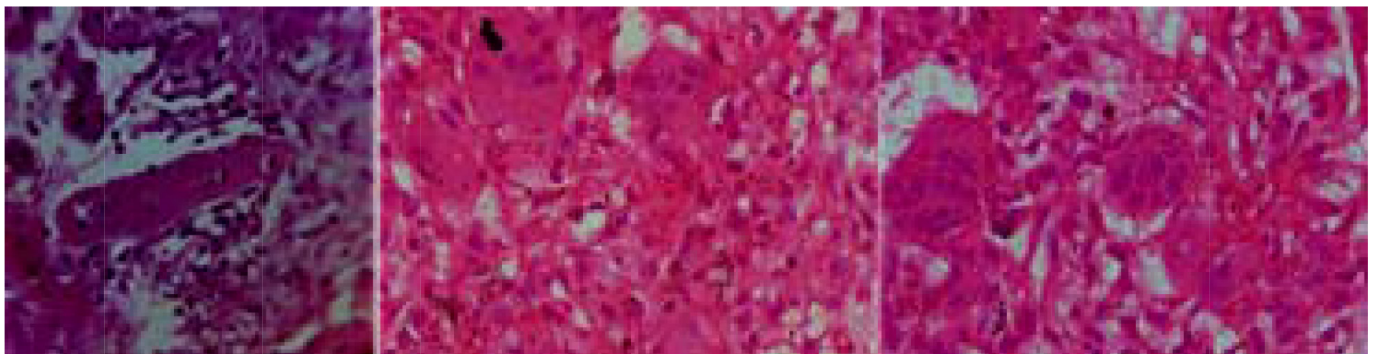

Fig 4: Numerous proliferating multinucleated giant cells within the background of plump ovoid and spindle-shaped mesenchymal cells, bony trabeculae, and many intervening congested blood vessels with foci of hemorrhage and inflammatory infiltrate (H and E, 10X and 40X)

diagnosis to CGCG.

There is no accepted algorithm for therapeutic intervention, and multiple treatment modalities have been used with varying degrees of success. Surgical treatment has been the traditionally accepted modality reducing the chances of recurrence²². Combined with appointments and follow-up with OMFS, we evolved into a plan of en bloc resection. Surgery was preferred over conservative treatment because of the relatively large size of the lesion, aggressive clinical course, and thinning out of cortical plates.²³

The recurrence rate is highly variable and depends on biological behavior and mode of treatment employed. However, in aggressive form, the recurrence rate after conventional therapy ranges from 20 to 70 percentage hence en bloc resection is recommended. En bloc resection with a 5mm margin is the modality of the treatment with the lowest recurrence.²⁴ In a study of 18 patients with aggressive CGCG by en bloc resection with a 5mm margin of healthy tissue, only one patient, had relapse.²⁴

The en bloc resection results in various degrees of deformity and damage to adjacent vital structures²⁵ care should be taken to preserve the vital structures and facial contours. It should be kept in mind that not all cases treated with en bloc resection were followed by bone reconstruction with an iliac crest graft^{9,(34-36)}. The decision to definitive reconstruction at the time of resection was inter-professional and was based on several goals and concerns. Any inflammation in the area of tumor by reconstruction may result in increased chances of recurrence, so it was decided to reconstruct after few years of follow up.

Regular monitoring is indispensable in all cases because of the significant potential for a relapse⁹.

CONCLUSION

Central giant cell granuloma should be considered in the differential diagnosis of any young child with a rapidly growing soft tissue lesion of the mandible. Prompt diagnosis and treatment can significantly improve morbidity and long-term outcomes. Further studies are required to determine the aggressive variant of CGCG.

REFERENCES

- Kruse-Losler B, Diallo R, Gaertner C, Mischke KL, Joos U, Kleinheinz J et al. Central giant cell granuloma of the jaws: A clinical, radiologic, and histopathologic study of 26 cases. *Oral Surg Oral Med Oral Pathol Oral Radiol Endod* 2006; 101:346-54.
- Jeyaraj P. Management of central giant cell granulomas of the jaws: An unusual case report with critical appraisal of existing literature. *Ann Maxillofac Surg* 2019; 9:37-47.
- Eisenbud L, Stern M, Rothberg M, Sachs SA. Central giant cell granuloma of the jaws: experience in the management of thirty-seven cases. *J Oral Maxillofac Surg*. 1988; 46(5):376-84.
- Jaffe HL. Giant-cell reparative granuloma, traumatic bone cyst, and fibrous (fibro-osseous) dysplasia of the jawbones. *Oral Surg Oral Med Oral Pathol*.1953;6(1):159-75.
- Jerkins D, Malotky M, Miremadi R, Dole M. Central Giant cell granuloma of the mandible requiring multiple treatment modalities: a case report. *J Oral*
- Jerkins D, Malotky M, Miremadi R, Dole M. Central giant cell granuloma of the mandible requiring multiple treatment modalities: a case report. *Journal of Oral and Maxillofacial Surgery*. 2016 Aug 1;74(8):1596-607.
- Gupta M, Gupta M, Singh S, Kaur R. Central giant cell granuloma of the maxilla. *BMJ Case Rep* 2013;2013. PII: bcr2013009102.
- De Lange J, van den Akker HP, van den Berg H. Central giant cell granuloma of the jaw: a review of the literature with emphasis on therapy options. *Oral Surg Oral Med Oral Pathol Oral Radiol Endod*. 2007;104(5):603-15.
- Kruse-Losler B, Diallo R, Gaertner C, Mischke KL, Joos U, Kleinheinz J. Central giant cell granuloma of the jaws: a clinical, radiologic, and histopathologic study of 26 cases. *Oral Surg Oral Med Oral Pathol Oral Radiol Endod*. 2006; 101(3):346-54.
- Chuong R, Kaban LB, Kozakewich H, Perez-Atayde A. Central giant cell lesions of the jaws: a clinicopathologic study. *J Oral Maxillofac Surg*. 1986;44(9):708-13.
- Saygun I, Sahin S, Muşabak U, et al. Human cytomegalovirus in peripheral giant cell granuloma. *Oral Microbiol Immunol* 2009; 24:408-10.
- Whitaker SB, Waldron CA. Central giant cell lesions of the jaws. A clinical, radiologic, and histopathologic study. *Oral Surg Oral Med Oral Pathol* 1993; 75:199-208.
- Chaparro-Avendaño AV, Berini-Aytés L, Gay-Escoda C. Peripheral giant cell granuloma. A report of five cases and review of the literature. *Med Oral Patol Oral Cir Bucal* 2005; 10:48-57.
- Flanagan AM, Nui B, Tinkler SM, et al. The multinucleate cells in giant cell granulomas of the jaw are osteoclasts. *Cancer* 1988; 62:1139-45.
- Yadav S, Singh A, Kumar P, Tyagi S. Recurrent case of central giant cell granuloma. *National Journal of Maxillofacial Surgery*. 2014;5(1). DOI: 10.4103/0975-5950.140181
- Jerkins D, Malotky M, Miremadi R, Dole M. Central Giant Cell Granuloma of the Mandible Requiring Multiple Treatment Modalities – A Case Report. *Journal of Oral and Maxillofacial Surgery*, 2016.
- Munzenmayer JY cols. Central giant cell granuloma of the mandibular condyle. Case-report. *Rev. Clin. Periodoncia Implantol. Rehabil. Oral*. 2013; 6(2):83-86.
- De Lange and van den Akker. Clinical and radiological features of central giant-cell lesions of the jaw. *Oral Surg Oral Med Oral Pathol Oral Radiol Endod*. 2005; 99:464-70.
- Scarfe WC, Farman AG. What is cone-beam CT, and how does it work? *Dent Clin North Am*.2008, 52:707-30.
- Syed AZ, Sin C, Rios R, Mupparapu M. Incidental occurrence of an unusually large mastoid foramen on cone-beam computed tomography and review of the literature. *Imaging Sci Dent*.2016, 46:39-45.
- Antoine Butel, Gemma Di Bernardo, Beatrice Louvet Central giant cell granuloma: a case report *J Oral Med Oral Surg* 2018;24:24-28.
- Barnes L, Eveson JW, Sidransky D, Reichart P, editors. *Pathology and genetics of head and neck tumours*. IARC; 2005.324.
- Adarsh Kudva, K.M. Cariappa, Vasantha, Monica Solomon. Central giant cell granuloma: An Uncommon presentation, *Oral and Maxillofacial Surgery Cases* (2018).
- Abdo EN, Alves LC, Rodrigues AS, Mesquita RA, Gomez RS. Treatment of a central giant cell granuloma with intralesional corticosteroid. *Br J Oral MaxillofacSurg* 2005; 43:74-6.
- Bataineh AB, Al-Khateeb T, Rawashed MA. The surgical treatment of central giant cell granuloma of the mandible. *J Oral Maxillofac Surg*. 2002; 60:756-761.
- Tabrizi R, Fardisi S, Zamiri B, Amanpour S, Karagah T. Can calcitonin nasal spray reduce the risk of recurrence of central giant cell granuloma of the jaws? A double-blind clinical trial. *Int J Oral Maxillofac Surg*. 2016 Jun;45(6):756-759.